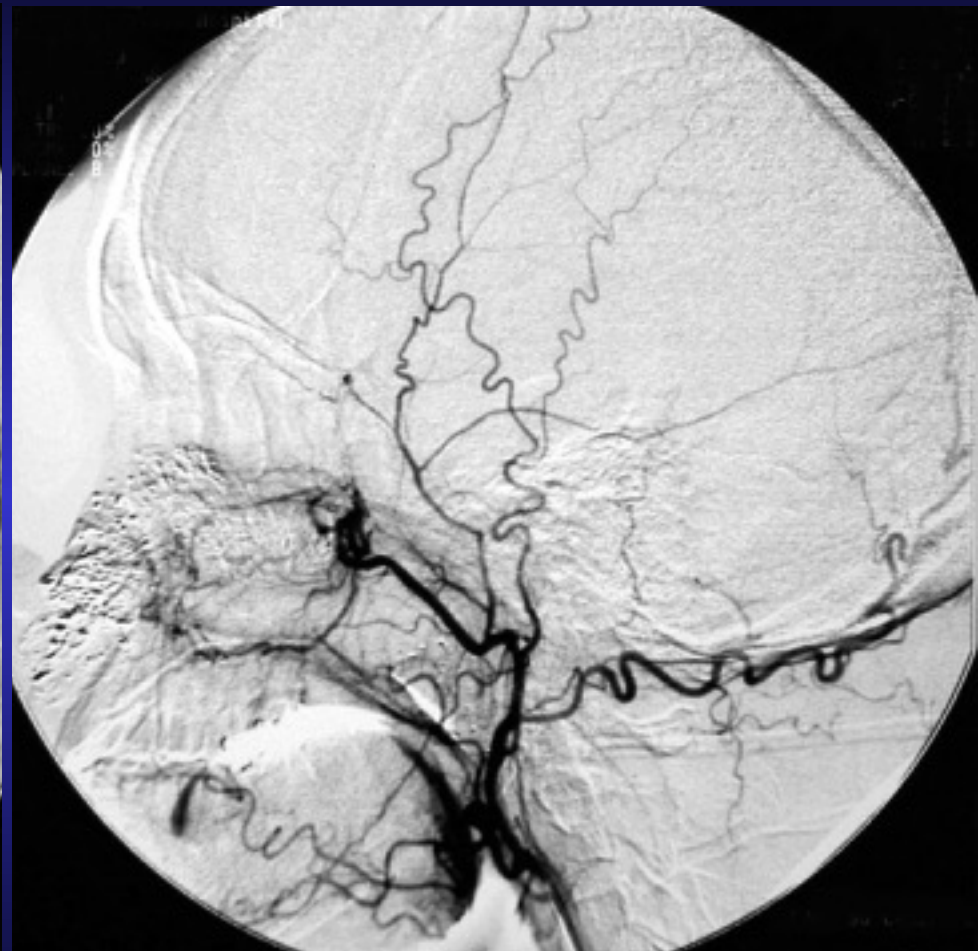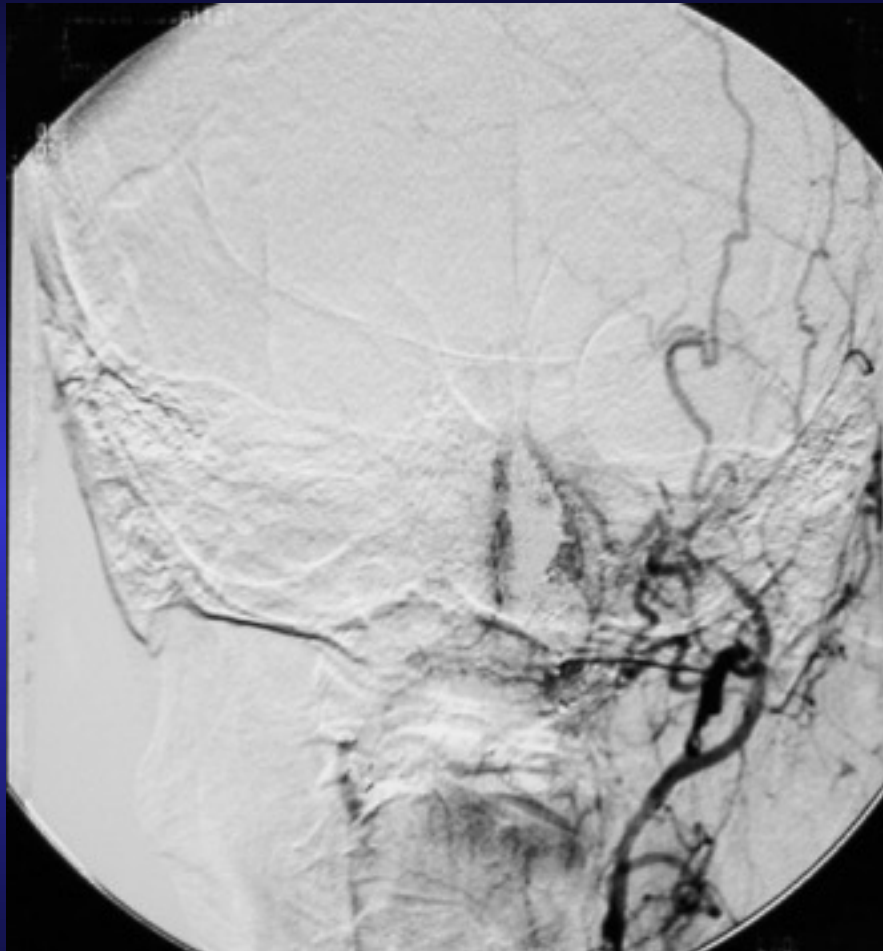


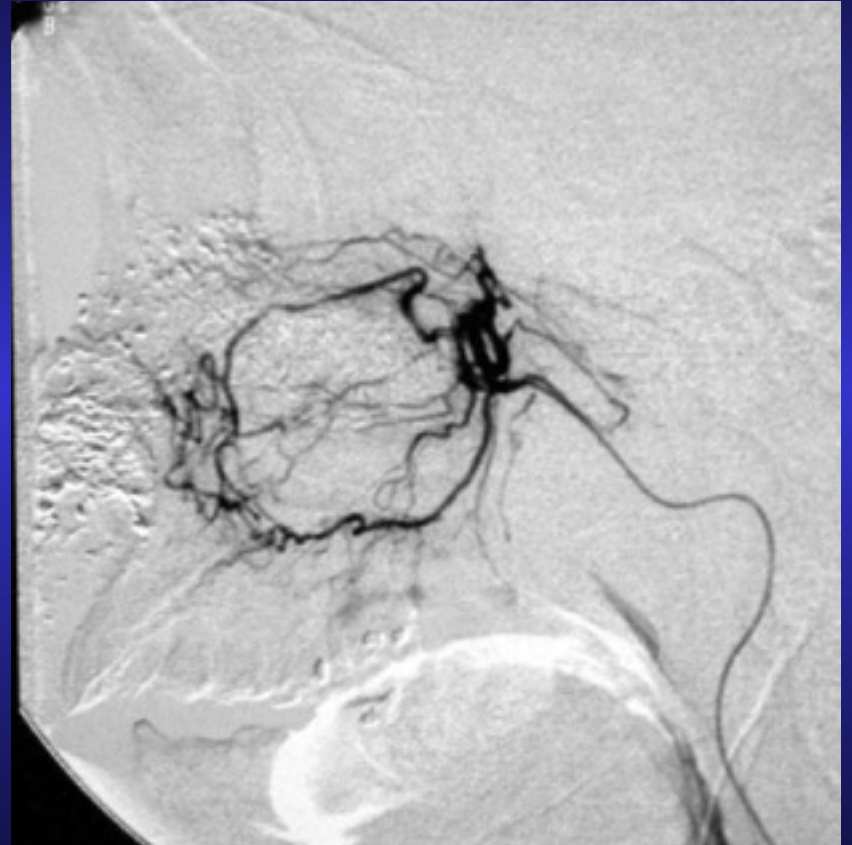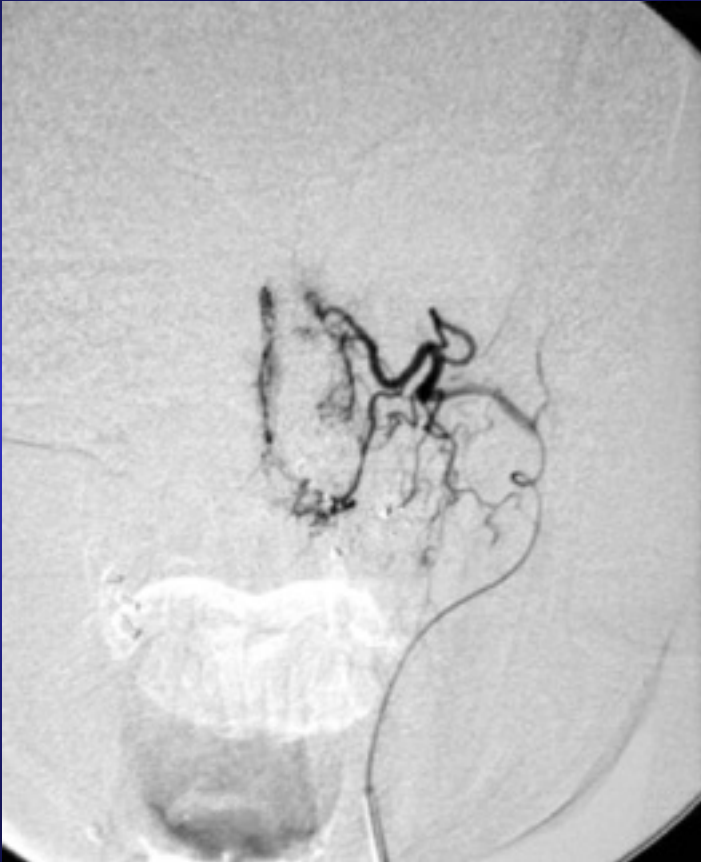Clinical case: Intractable epistaxis

- M/50
- c/o severe epistaxis
- Can only be stopped by nasal packing
- Treatment with transarterial embolization



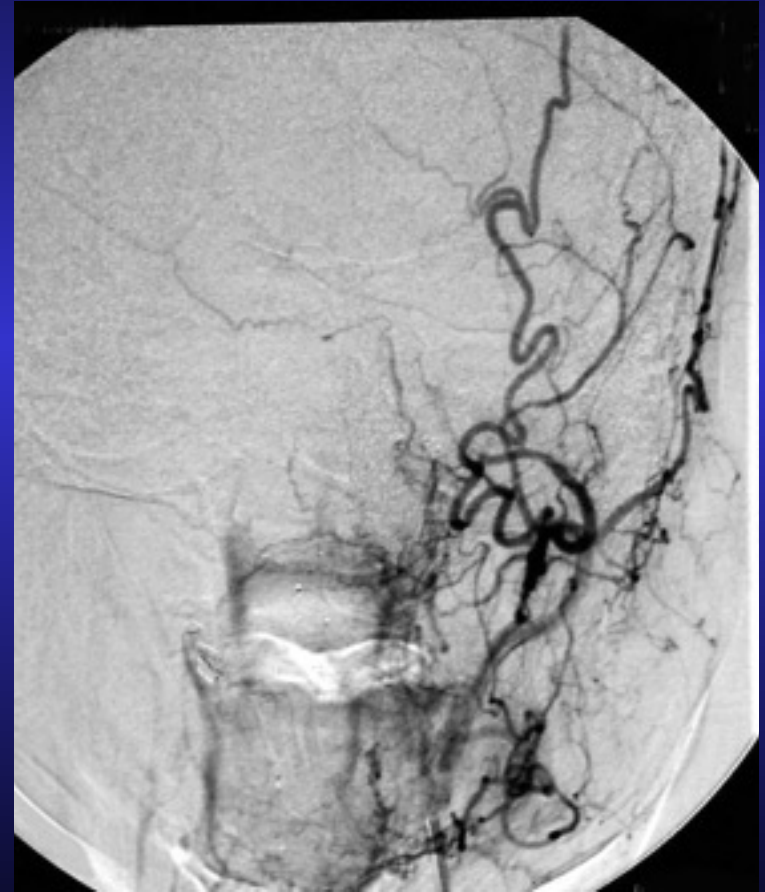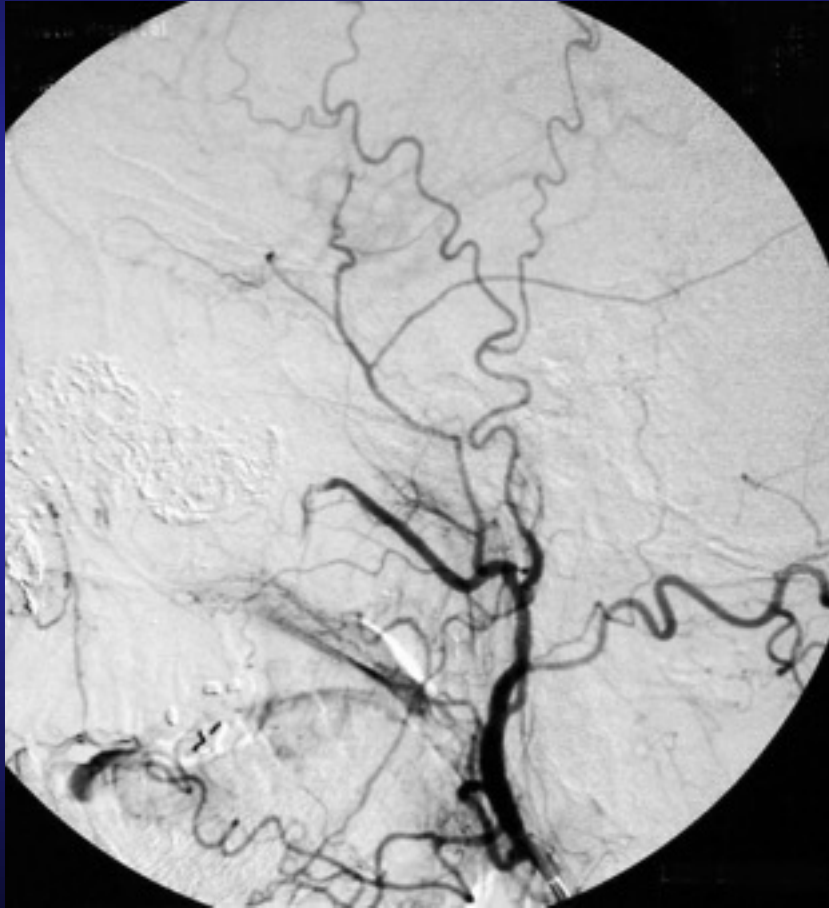
Left external carotid arteriogram

Embolization with PVA particles



Selective left IMA arteriogram

Devascularization of IMA territory



Post-embolization left ECA arteriogram